

ORIGINAL ARTICLE

Ranibizumab versus Verteporfin for Neovascular Age-Related Macular Degeneration

David M. Brown, M.D., Peter K. Kaiser, M.D., Mark Michels, M.D., Gisele Soubrane, M.D., Jeffrey S. Heier, M.D., Robert Y. Kim, M.D., Judy P. Sy, Ph.D., and Susan Schneider, M.D., for the ANCHOR Study Group*

ABSTRACT

BACKGROUND

From Vitreoretinal Consultants, Methodist Hospital, Houston (D.M.B.); the Cole Eye Institute, Cleveland Clinic Foundation, Cleveland (P.K.K.); Retina Care Specialists, Palm Beach Gardens, FL (M.M.); the Clinique d'Ophtalmologie, University of Paris XII, Créteil, France (G.S.); Ophthalmic Consultants of Boston, Boston (J.S.H.); and Genentech, South San Francisco, CA (R.Y.K., J.P.S., S.S.). Address reprint requests to Dr. Brown at Vitreoretinal Consultants, 6560 Fannin St., Suite 750, Houston, TX 77030, or at dmbmd@houstonretina.com.

We compared ranibizumab — a recombinant, humanized, monoclonal antibody Fab that neutralizes all active forms of vascular endothelial growth factor A — with photodynamic therapy with verteporfin in the treatment of predominantly classic neovascular age-related macular degeneration.

METHODS

During the first year of this 2-year, multicenter, double-blind study, we randomly assigned patients in a 1:1:1 ratio to receive monthly intravitreal injections of ranibizumab (0.3 mg or 0.5 mg) plus sham verteporfin therapy or monthly sham injections plus active verteporfin therapy. The primary end point was the proportion of patients losing fewer than 15 letters from baseline visual acuity at 12 months.

RESULTS

Of the 423 patients enrolled, 94.3% of those given 0.3 mg of ranibizumab and 96.4% of those given 0.5 mg lost fewer than 15 letters, as compared with 64.3% of those in the verteporfin group ($P < 0.001$ for each comparison). Visual acuity improved by 15 letters or more in 35.7% of the 0.3-mg group and 40.3% of the 0.5-mg group, as compared with 5.6% of the verteporfin group ($P < 0.001$ for each comparison). Mean visual acuity increased by 8.5 letters in the 0.3-mg group and 11.3 letters in the 0.5-mg group, as compared with a decrease of 9.5 letters in the verteporfin group ($P < 0.001$ for each comparison). Among 140 patients treated with 0.5 mg of ranibizumab, presumed endophthalmitis occurred in 2 patients (1.4%) and serious uveitis in 1 (0.7%).

CONCLUSIONS

Ranibizumab was superior to verteporfin as intravitreal treatment of predominantly classic neovascular age-related macular degeneration, with low rates of serious ocular adverse events. Treatment improved visual acuity on average at 1 year. (ClinicalTrials.gov number, NCT00061594.)

*Principal investigators in the Anti-VEGF Antibody for the Treatment of Predominantly Classic Choroidal Neovascularization in Age-Related Macular Degeneration (ANCHOR) Study Group are listed in the Appendix.

N Engl J Med 2006;355:1432-44.
Copyright © 2006 Massachusetts Medical Society.

AGE-RELATED MACULAR DEGENERATION is a leading cause of severe and irreversible vision loss in the developed world among people 50 years of age or older.¹⁻⁴ The neovascular form of the disease is characterized by the growth of abnormal, choroidal blood vessels beneath the macula, which causes severe loss of vision.⁵ Two main patterns of choroidal neovascularization that are associated with age-related macular degeneration, as seen on fluorescein angiography, are classic (in which intensely bright fluorescence is seen in early phases of the angiogram and leaks in late phases) and occult (in which leakage is less intense and appears in the late phases of disease).⁶ Choroidal neovascular lesions that are predominantly (50% or more) classic in composition cause more severe and more rapid loss of vision than do lesions that are minimally (less than 50%) classic or occult.^{7,8}

Photodynamic therapy with verteporfin⁹⁻¹² and intravitreal administration of pegaptanib sodium are approved by the Food and Drug Administration (FDA) and the European Agency for the Evaluation of Medicinal Products for the treatment of neovascular age-related macular degeneration.¹³ Neither treatment has resulted in clinically significant improvements in visual acuity.

Ranibizumab — a recombinant, humanized monoclonal antibody Fab that neutralizes all active forms of vascular endothelial growth factor A (VEGF-A) — was recently approved by the Food and Drug Administration for the treatment of this condition. Elsewhere in this issue of the *Journal*, Rosenfeld et al. report on a phase 3 study, called the Minimally Classic/Occult Trial of the Anti-VEGF Antibody Ranibizumab in the Treatment of Neovascular Age-Related Macular Degeneration (MARINA),¹⁴ which demonstrated that monthly intravitreal injections of ranibizumab prevented the loss of visual acuity in approximately 95% of patients and improved visual acuity in one quarter to one third of treated patients during 24 months of treatment. In a similar manner, the addition of ranibizumab to verteporfin photodynamic therapy in patients with predominantly classic choroidal neovascularization was associated with a reduction in the loss of visual acuity, as compared with verteporfin therapy alone, and with an improvement in visual acuity over baseline in many patients.¹⁵ We report the first-year results of a 2-year, phase 3 study, which compared the efficacy and safety of repeated intravitreal

injections of ranibizumab with that of photodynamic therapy with verteporfin in patients with predominantly classic lesions associated with neovascular age-related macular degeneration.

METHODS

STUDY DESIGN

The Anti-VEGF Antibody for the Treatment of Predominantly Classic Choroidal Neovascularization in Age-Related Macular Degeneration (ANCHOR) trial was an international, multicenter, randomized, double-blind, active-treatment-controlled study. Before the initiation of the study, we obtained approval from institutional review boards or ethics committees at all clinical centers. Patients provided written informed consent for study participation. Screening lasted as long as 28 days.

For inclusion in the study, patients had to be at least 50 years of age; have a lesion whose total size was no more than 5400 μm in greatest linear dimension in the study eye; have best-corrected visual acuity of 20/40 to 20/320 (Snellen equivalent), assessed with the use of Early Treatment Diabetic Retinopathy Study (ETDRS) charts; have no permanent structural damage to the central fovea; and have had no previous treatment (including verteporfin therapy) that might compromise an assessment of the study treatment. No patients were excluded because of preexisting cardiovascular, cerebrovascular, or peripheral vascular conditions.

STUDY TREATMENT

We randomly assigned eligible patients in a 1:1:1 ratio to receive either 0.3 or 0.5 mg of ranibizumab (Lucentis, Genentech) plus sham verteporfin therapy or sham intravitreal injections plus active verteporfin therapy. Randomization was stratified according to study center and to visual-acuity scores on day 0 (<45 letters vs. \geq 45 letters, with a score of 45 letters as the approximate Snellen equivalent of 20/125 vision). In the group that received photodynamic therapy with verteporfin, intravenous administration of verteporfin (Visudyne, Novartis Pharmaceuticals) was followed by laser irradiation of the macula, according to instructions provided in the product package insert (www.visudyne.com). In the ranibizumab groups, sham verteporfin therapy was achieved by an intravenous infusion of saline rather than verteporfin, followed by laser

Table 1. Baseline Characteristics of the Patients.*

Characteristic	Verteporfin (N=143)	0.3 mg of Ranibizumab (N=140)	0.5 mg of Ranibizumab (N=140)
Sex — no. (%)			
Male	64 (44.8)	73 (52.1)	75 (53.6)
Female	79 (55.2)	67 (47.9)	65 (46.4)
Race — no. (%)†			
White	140 (97.9)	137 (97.9)	136 (97.1)
Other	3 (2.1)	3 (2.1)	4 (2.9)
Age — yr			
Mean	77.7±7.8	77.4±7.5	76.0±8.6
Range	53–95	54–97	54–93
Age group — no. (%)			
50–64 yr	8 (5.6)	9 (6.4)	14 (10.0)
65–74 yr	35 (24.5)	28 (20.0)	41 (29.3)
75–84 yr	74 (51.7)	84 (60.0)	64 (45.7)
≥85 yr	26 (18.2)	19 (13.6)	21 (15.0)
Previous therapy — no. (%)			
Any treatment	64 (44.8)	63 (45.0)	58 (41.4)
Laser photocoagulation	19 (13.3)	23 (16.4)	20 (14.3)
Medication	1 (0.7)	1 (0.7)	1 (0.7)
Nutritional supplements	51 (35.7)	48 (34.3)	45 (32.1)
No. of letters read as a measure of visual acuity‡§			
Mean	45.5±13.1	47.0±13.1	47.1±13.2
<45 — no. (%)	66 (46.2)	63 (45.0)	60 (43.2)
≥45 — no. (%)	77 (53.8)	77 (55.0)	79 (56.8)

irradiation of the macula identical to that in the active verteporfin-therapy group.

Ranibizumab was injected into the study eye at a monthly interval (ranging from 23 to 37 days, for a total of 12 injections, excluding the injection at month 12) in the first year, beginning on day 0; sham injections were administered on the same schedule. Either verteporfin or sham verteporfin was administered on day 0 and then if needed on the basis of investigators' evaluation of angiography at months 3, 6, 9, or 12.

The study was designed and analyzed by a committee composed of Dr. Brown, representing the academic investigators, and representatives of Genentech. In analyzing the data and writing this manuscript, Dr. Brown had full and unrestricted access to the data, and all coauthors contributed to the interpretation of the data and the writing of the manuscript. The authors vouch for the accuracy and completeness of the reported data.

STATISTICAL ANALYSIS

We performed efficacy analyses on an intention-to-treat basis with the use of a last-observation-carried-forward method for missing data. Pairwise treatment comparisons were performed with the use of statistical methods adjusting for baseline scores of visual acuity (<45 letters vs. ≥45 letters) and, for lesion morphologic end points, the baseline value of the lesion characteristic. Binary end points were analyzed with the use of the Cochran chi-square test.¹⁶ Mean changes from baseline were analyzed with the use of analysis of variance for end points with respect to visual acuity and an analysis of covariance for morphologic end points. The Hochberg–Bonferroni multiple-comparison procedure¹⁷ was used to adjust for the two pairwise treatment comparisons of the primary end point. Safety analyses included all treated patients.

The number of patients required for statistical

Table 1. (Continued.)

Characteristic	Verteporfin (N=143)	0.3 mg of Ranibizumab (N=140)	0.5 mg of Ranibizumab (N=140)
Visual acuity (approximate Snellen equivalent) — no. (%) ^{‡§}			
20/200 or worse	46 (32.2)	35 (25.0)	32 (23.0)
Better than 20/200 but worse than 20/40	97 (67.8)	103 (73.6)	101 (72.7)
20/40 or better	0	2 (1.4)	6 (4.3)
Type of choroidal neovascularization — no. (%)			
Predominantly classic lesion	141 (98.6)	134 (95.7)	135 (96.4)
Minimally classic lesion	2 (1.4)	5 (3.6)	5 (3.6)
Occult with no classic lesion	0	1 (0.7)	0
Size of lesion — optic-disk area [¶]			
Mean	1.88±1.40	1.89±1.44	1.79±1.54
Range	0.07–5.75	0.12–7.20	0.05–10.00
Size of choroidal neovascularization — optic-disk area [¶]			
Mean	1.48±1.25	1.48±1.33	1.31±1.24
Range	0.07–5.55	0.11–6.80	0.05–7.50
Size of classic choroidal neovascularization — optic-disk area [¶]			
Mean	1.36±1.13	1.28±1.05	1.21±1.12
Range	0.07–5.55	0.00–6.40	0.05–5.30
Size of leakage from choroidal neovascularization plus staining of retinal pigment epithelium — optic-disk area [¶]			
Mean	3.06±1.81	3.00±1.92	2.92±2.08
Range	0.20–8.20	0.20–11.00	0.25–9.0

* Plus-minus values are means ±SD. Percentages may not total 100 because of rounding.

† Race was determined by the investigators.

‡ Visual acuity was measured with the use of Early Treatment Diabetic Retinopathy Study charts at a starting distance of 2 m. A score of 45 letters is the approximate Snellen equivalent of 20/125.

§ For the group that received 0.5 mg of ranibizumab, 139 patients were observed.

¶ One optic-disk area is equal to 2.54 mm² on the basis of one optic-disk diameter of 1.8 mm.

significance was determined on the basis of a 1:1:1 randomization ratio, the Pearson chi-square test for the two pairwise comparisons of the primary end point, and the Hochberg–Bonferroni multiple-comparison procedure at an overall type I error of 0.0497. We estimated that the enrollment of 426 patients would provide the study with a statistical power of 96% to detect a significant difference between one or both ranibizumab groups and the verteporfin group in the percentage of patients losing fewer than 15 letters at 12 months, assuming a rate of 84% in each ranibizumab group and 67% in the sham verteporfin group. (See the Supplementary Appendix, available with the full text of this article at www.nejm.org, for additional information on the study design and analysis.)

RESULTS

STUDY PATIENTS

Between June 2003 and September 2004, 423 patients were enrolled and randomly assigned to a study treatment (143 to the verteporfin group and 140 to each of the ranibizumab groups). The disposition of the patients is summarized in Table 1 of the Supplementary Appendix. Three patients in the group receiving 0.3 mg of ranibizumab did not receive any treatment: one because of the patient's decision and two because of an investigator's decision. More than 90% of patients in each group (91.5% overall) were receiving treatment at 12 months. Of a possible 12 injections of ranibizumab or sham injections, the mean number administered was 11.1 in the verteporfin group,

11.0 in the 0.3-mg group, and 11.2 in the 0.5-mg group. Including the required administration on day 0 and excluding month 12, active verteporfin therapy was administered a mean of 2.8 times in the verteporfin group, and sham verteporfin was administered a mean of 1.7 times in each of the ranibizumab groups.

Randomized treatment groups were balanced for demographic and baseline ocular and morphologic characteristics (Table 1). The independent reading center subtended the choroidal neovascularization as predominantly classic in all patients during the expedited screening evaluation. Subsequent reevaluation confirmed the initial classification in 96.9% of patients, and 3.1% were reclassified. In each group, the mean total lesion area was slightly less than 2 optic-disk areas (1 optic-disk area equals 2.54 mm² on the basis of 1 optic-disk diameter of 1.8 mm).

PRIMARY AND SECONDARY END POINTS

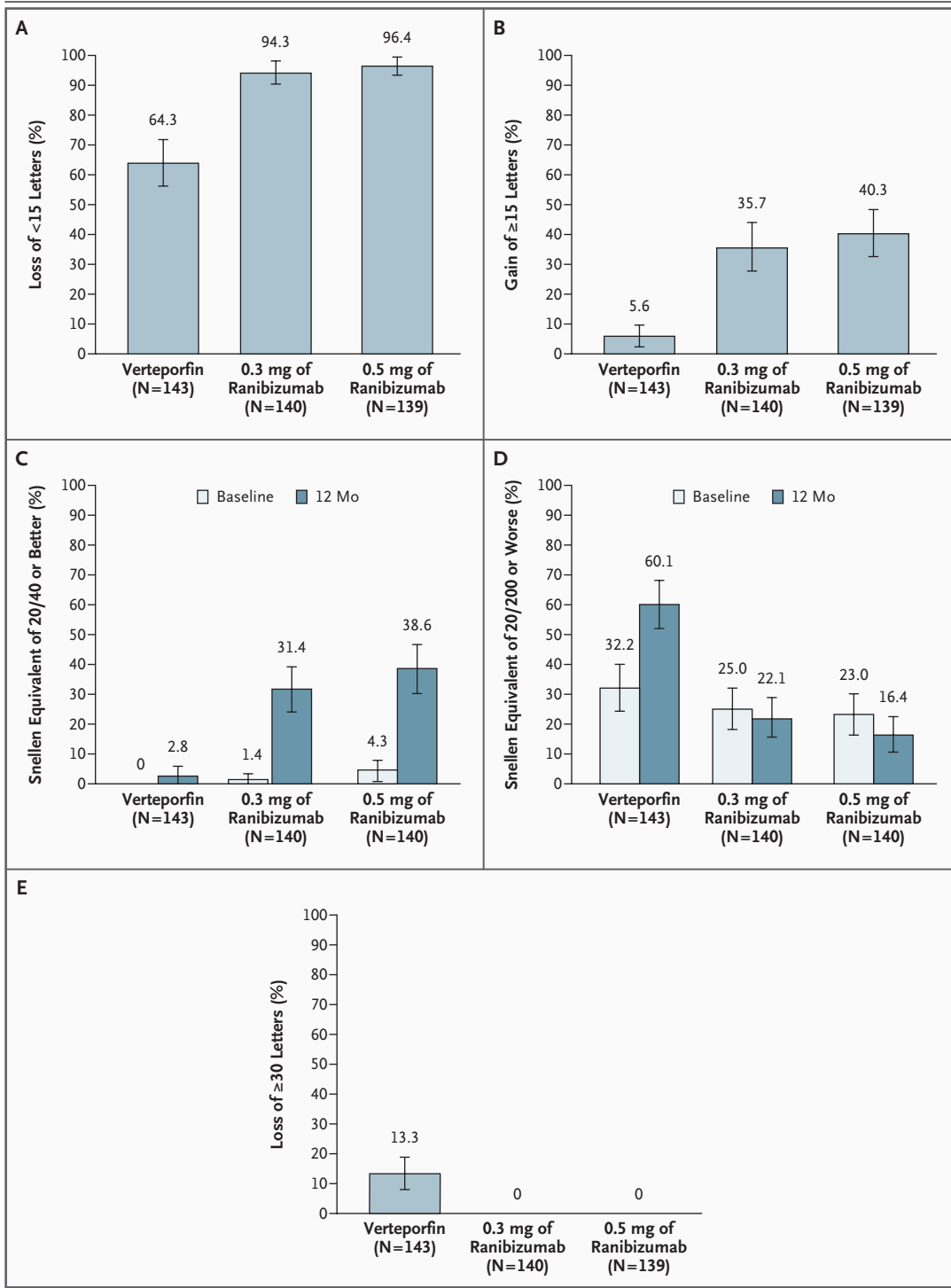
All end points with respect to visual acuity in the study eye at 12 months favored ranibizumab treatment over verteporfin therapy. With respect to the primary efficacy end point, 94.3% of patients in the 0.3-mg group and 96.4% in the 0.5-mg group lost fewer than 15 letters from baseline visual acuity, as compared with 64.3% in the verteporfin group ($P < 0.001$ for each comparison) (Fig. 1A). In addition, the proportion of patients whose visual acuity improved from baseline by 15 or more letters was significantly greater among those receiving ranibizumab treatment (35.7% in the 0.3-mg group and 40.3% in the 0.5-mg group, as compared with 5.6% in the verteporfin group; $P < 0.001$ for each comparison) (Fig. 1B). Significantly greater proportions of ranibizumab-treated patients than patients in the verteporfin group had visual acuity of 20/40 or better ($P < 0.001$ for the comparison of each ranibizumab group with the verteporfin group) (Fig. 1C), and smaller proportions had visual acuity of 20/200 or worse ($P < 0.001$ for each comparison) (Fig. 1D). A severe loss of visual acuity (defined as a decrease of 30 letters or more) did not occur in any patient in the ranibizumab groups but occurred in 13.3% of patients in the verteporfin group ($P < 0.001$ for each comparison) (Fig. 1E). Although no patient had baseline visual acuity of 20/20 or better, at 12 months 7.1% of the patients in the 0.3-mg group and 6.4% in the 0.5-mg group had visual acuity of 20/20 or better, as compared with 0.7% of patients in the verteporfin group.

Figure 1 (facing page). Visual Acuity Scores and Snellen Equivalents at 12 Months.

Panel A shows the percentage of patients who lost fewer than 15 letters (moderate loss) from baseline visual acuity at 12 months (the primary efficacy end point). Panel B shows the percentage of patients who gained 15 or more letters (moderate gain) from baseline at 12 months. Panels C and D show the percentage of patients with vision of the Snellen equivalent of 20/40 or better and of those with vision of 20/200 or worse, respectively, at both baseline and 12 months. (For the group that received 0.5 mg of ranibizumab, 139 patients were observed at baseline and 140 patients were observed at 12 months in Panels C and D.) Panel E shows the percentage of patients who lost 30 or more letters (severe loss) from baseline at 12 months. Treatment comparisons were based on the Cochran chi-square test stratified according to the visual-acuity score on day 0 (<45 letters vs. ≥ 45 letters). Confidence intervals, denoted by I bars, were based on the normal approximation and the simple (unstratified) estimates of the percentages and their standard errors. The last-observation-carried-forward method was used to impute missing data. All statistical tests were two-sided. $P < 0.001$ for all comparisons of each dose of ranibizumab with verteporfin.

The tracking of mean changes in visual-acuity scores over time showed that the values in each of the ranibizumab groups were significantly superior to those in the verteporfin group at each month during the first year ($P < 0.001$) (Fig. 2). On average, visual acuity of ranibizumab-treated patients increased by 5.9 letters in the 0.3-mg group and 8.4 letters in the 0.5-mg group at 1 month after the first treatment and increased further over time to a gain of 8.5 letters in the 0.3-mg group and 11.3 letters in the 0.5-mg group by 12 months. In contrast, the verteporfin group had an average loss in visual acuity at each month after the first month, with a mean loss of 9.5 letters by 12 months. Results for all end points with respect to visual acuity at 12 months were similar when the analyses used the observed data with no imputation of missing values (data not shown).

Results for prespecified secondary end points related to the morphologic characteristics of lesions are summarized in Table 2. At 12 months, the area occupied by classic choroidal neovascularization decreased by a mean of 0.52 optic-disk area in the 0.3-mg group and 0.67 optic-disk area in the 0.5-mg group, as compared with a mean increase of 0.54 optic-disk area in the verteporfin group ($P < 0.001$ for each comparison). The area of leakage from choroidal neovascularization plus



intense, progressive staining of the retinal pigment epithelium at 12 months decreased by a mean of 1.80 optic-disk areas in the 0.3-mg group and 2.05 optic-disk areas in the 0.5-mg group, as compared with a mean increase of 0.32 optic-

disk area in the verteporfin group ($P < 0.001$ for each comparison). Figure 3 shows a representative patient with a reduction in the area of chorioidal neovascularization and leakage from baseline to 12 months.

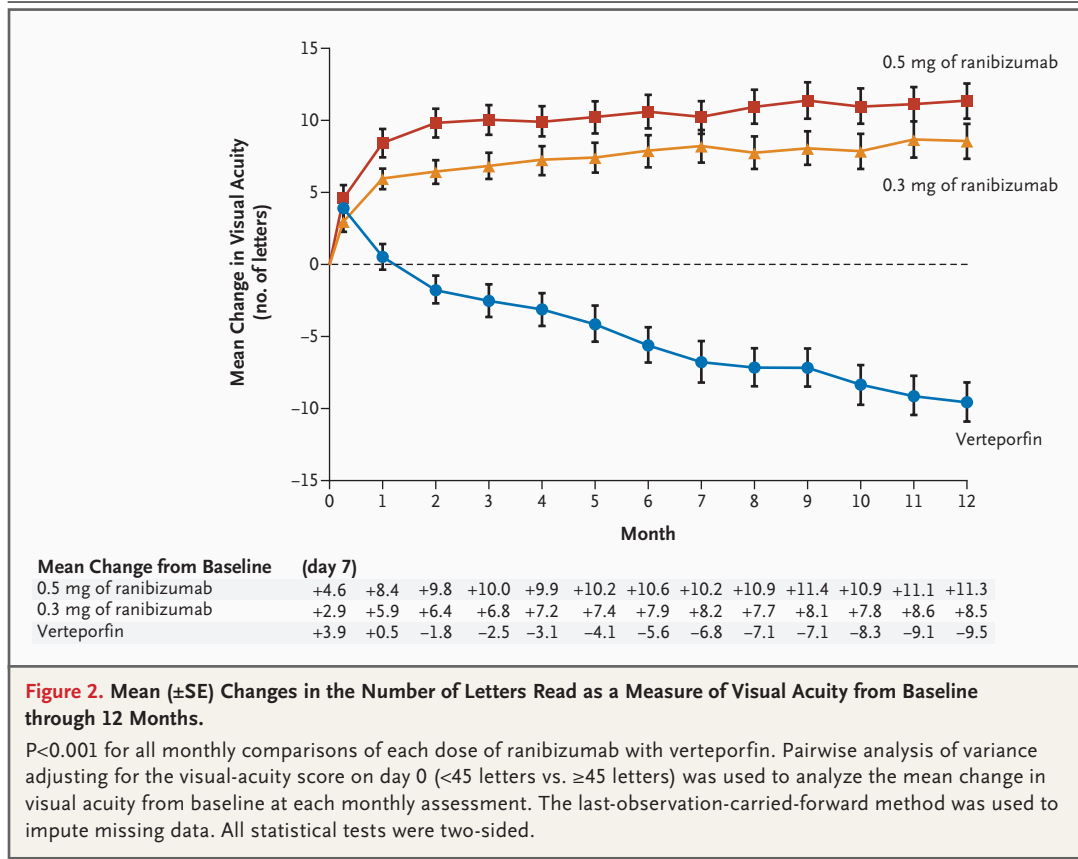


Figure 2. Mean (\pm SE) Changes in the Number of Letters Read as a Measure of Visual Acuity from Baseline through 12 Months.

$P < 0.001$ for all monthly comparisons of each dose of ranibizumab with verteporfin. Pairwise analysis of variance adjusting for the visual-acuity score on day 0 (< 45 letters vs. ≥ 45 letters) was used to analyze the mean change in visual acuity from baseline at each monthly assessment. The last-observation-carried-forward method was used to impute missing data. All statistical tests were two-sided.

The area occupied by choroidal neovascularization (classic and occult, if present) increased by a mean of 1.63 optic-disk areas in the verteporfin group, as compared with small mean increases of 0.20 optic-disk area in the 0.3-mg group and 0.22 optic-disk area in the 0.5-mg group ($P < 0.001$ for each comparison). The mean lesion area increased in the verteporfin group to 2.56 optic-disk areas, as compared with small increases in the ranibizumab groups of 0.36 optic-disk area in the 0.3-mg group and 0.28 optic-disk area in the 0.5-mg group ($P < 0.001$ for each comparison).

ADVERSE EVENTS

Safety results are summarized in Table 3. Serious ocular adverse events associated with treatment were uncommon. Endophthalmitis, classified as a condition treated with intravitreal or systemic antibiotics, was reported in one patient, who was in the 0.5-mg group (0.7%). An additional patient in the 0.5-mg group (0.7%) had two events of intraocular inflammation that were classified by the investigator as serious uveitis. However, since

one of the events was treated with systemic antibiotics (without obtaining ocular culture specimens or treatment with intravitreal antibiotics), this patient was presumed to have had endophthalmitis, and was so classified in Table 3. Rhegmatogenous retinal detachment occurred in one patient (0.7%) in the 0.3-mg group and one in the verteporfin group, and vitreous hemorrhage occurred in one patient (0.7%) in the 0.3-mg group.

Rates of adverse events of intraocular inflammation (pooled for reported events of iritis, iridocyclitis, vitritis, uveitis, and anterior-chamber inflammation) were higher in both ranibizumab groups (10.2% in the 0.3-mg group and 15.0% in the 0.5-mg group) than in the verteporfin group (2.8%). Rates of intraocular inflammation (regardless of cause) observed during slit-lamp examination were consistent with those reported as adverse events (12.4% in the 0.3-mg group and 17.1% in the 0.5-mg group, as compared with 3.5% in the verteporfin group). Most patients in all groups had no observable inflammation during the study, and the proportion of inflammation events graded 2+ or higher among ranibizumab-treated pa-

Table 2. Summary of Changes from Baseline in Morphologic Characteristics of Lesions at 12 Months.*

End Point	Verteporfin (N=143)	0.3 mg of Ranibizumab (N=140)	0.5 mg of Ranibizumab (N=140)	P Value†
Change in size of classic choroidal neovascularization (optic-disk area)‡				
Mean	0.54±2.37	-0.52±0.89	-0.67±1.10	<0.001
95% CI	0.15 to 0.93	-0.67 to -0.37	-0.86 to -0.49	
Change in size of leakage from choroidal neovascularization plus staining of retinal pigment epithelium (optic-disk area)‡				
Mean	0.32±3.09	-1.80±1.72	-2.05±1.98	<0.001
95% CI	-0.19 to 0.83	-2.09 to -1.51	-2.38 to -1.72	
Change in size of choroidal neovascularization (classic lesion plus occult lesion, if present) (optic-disk area)‡				
Mean	1.63±2.37	0.20±0.97	0.22±1.25	<0.001
95% CI	1.23 to 2.02	0.04 to 0.37	0.01 to 0.42	
Change in size of lesion (optic-disk area)‡				
Mean	2.56±3.09	0.36±1.06	0.28±1.29	<0.001
95% CI	2.05 to 3.07	0.18 to 0.53	0.06 to 0.49	

* Plus-minus values are means ±SD. CI denotes confidence interval.

† P values are for the comparison of each dose of ranibizumab with verteporfin therapy. Comparisons were based on pairwise analysis-of-covariance models adjusted for the stratification variable (a baseline visual-acuity score of <45 letters or ≥45 letters) and the baseline value of the end point. The last-observation-carried-forward method was used to impute missing data. All statistical tests were two-sided.

‡ One optic-disk area is equal to 2.54 mm² on the basis of 1 optic-disk diameter of 1.8 mm.

tients was small: three patients in each dose group (2.2% in the 0.3-mg group and 2.1% in the 0.5-mg group).

Transient changes in intraocular pressure after injection were common in the ranibizumab-treated patients. The proportion of patients with a postinjection intraocular pressure of 30 mm Hg or more was greater in both ranibizumab groups (8.8% in the 0.3-mg group and 8.6% in the 0.5-mg group) than in the verteporfin group (4.2%). However, very few patients had measurements of 40 mm Hg or more (2.9% in each ranibizumab group vs. 0.7% in the verteporfin group).

The ranibizumab groups had an increased frequency of cataract formation (10.9% in the 0.3-mg group and 12.9% in the 0.5-mg group, as compared with 7.0% in the verteporfin group). With the exception of one severe cataract in the verteporfin group, all adverse events associated with cataracts were mild or moderate. A small number of patients had changes in lens status reported during the first treatment year. Of patients whose study eye was phakic at baseline, five underwent

cataract surgery during the 12 months of the study: four (5.3%) in the 0.3-mg group and one (1.2%) in the 0.5-mg group, as compared with none in the verteporfin group. Visual-acuity outcomes of these patients at 12 months were not notably different from those of the respective treatment groups overall. No traumatic lens damage was reported in the study eye of any patient during the first treatment year.

There was no overall imbalance among groups in the rates of serious nonocular adverse events: 14.6% in the 0.3-mg group and 20.0% in the 0.5-mg group, as compared with 19.6% in the verteporfin group. The numbers of deaths were similar across groups: three patients (2.2%) in the 0.3-mg ranibizumab group and two patients each (1.4%) in the 0.5-mg group and verteporfin group. With respect to specific nonocular adverse events, there were imbalances in back pain and nonocular hemorrhage (a combination of serious and nonserious events). Back pain was less common in the ranibizumab groups (3.6% in the 0.3-mg group and 1.4% in the 0.5-mg group) than in the

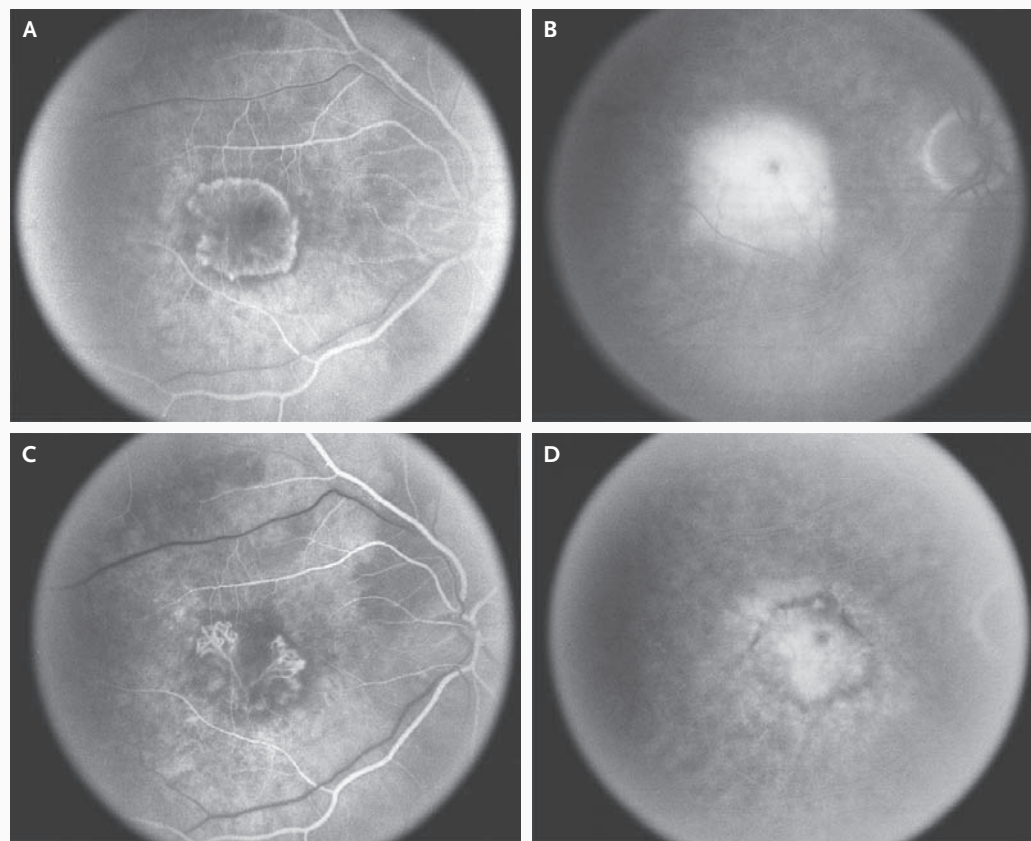


Figure 3. Fundus Fluorescein Angiography in a 79-Year-Old Patient.

The patient presented with a best-corrected visual acuity of 20/100 and was randomly assigned to the group receiving 0.3 mg of ranibizumab. The early-phase angiogram shows a predominantly classic lesion (Panel A); intense leakage is visible in the late phase (Panel B). At 12 months, the patient's visual acuity had improved by 3 lines to 20/50. Repeated angiography shows involution of the classic choroidal neovascularization (Panel C) with a reduction in leakage in the late phase (Panel D).

verteporfin group (9.1%) and is a well-known potential adverse reaction to verteporfin infusion.¹⁸ The incidence of nonocular hemorrhage, an adverse event that potentially reflects systemic VEGF inhibition,¹⁹ was higher in the ranibizumab groups (5.1% in the 0.3-mg group and 6.4% in the 0.5-mg group, as compared with 2.1% in the verteporfin group). There was no increase in the ranibizumab groups in mean systolic or diastolic blood pressure or in the rates of hypertension and proteinuria, other adverse events potentially reflecting systemic VEGF inhibition.

Serious adverse events of arterial thromboembolism were evaluated with the use of the Antiplatelet Trialists' Collaboration (APTIC) criteria, in which an event is defined as a nonfatal myocardial infarction, nonfatal ischemic stroke, nonfatal

hemorrhagic stroke, or death owing to vascular or unknown causes.²⁰ Overall, APTC-classified arterial thromboembolic events occurred in three patients (2.2%) in the 0.3-mg group, six patients (4.3%) in the 0.5-mg group, and three patients (2.1%) in the verteporfin group (Table 3). One patient (0.7%) in each group had a nonfatal cerebrovascular event. Nonfatal myocardial infarction occurred in one patient (0.7%) in the 0.3-mg group, three patients (2.1%) in the 0.5-mg group, and in one patient (0.7%) in the verteporfin group. No apparent relationship between the onset of those events and the time of study treatment was observed; the differences were not significant. One patient in the 0.3-mg group who began concomitant treatment with the systemic anti-VEGF agent bevacizumab for metastatic cancer midway through

Table 3. Adverse Events.*

Adverse Event	Verteporfin (N = 143)	0.3 mg of Ranibizumab (N = 137)	0.5 mg of Ranibizumab (N = 140)
Serious ocular adverse event — no. (%)			
Presumed endophthalmitis†	0	0	2 (1.4)
Culture positive	0	0	1 (0.7)‡
Culture not obtained	0	0	1 (0.7)
Uveitis	0	0	1 (0.7)§
Rhegmatogenous retinal detachment	1 (0.7)¶	1 (0.7)	0
Retinal tear	0	0	0
Vitreous hemorrhage	0	1 (0.7)	0
Lens damage	0	0	0
Most severe ocular inflammation — no. (%)**			
None	138 (96.5)	120 (87.6)	116 (82.9)
Trace	4 (2.8)	11 (8.0)	13 (9.3)
1+	1 (0.7)	3 (2.2)	8 (5.7)
2+	0	1 (0.7)	1 (0.7)
3+	0	2 (1.5)	1 (0.7)
4+	0	0	1 (0.7)
Nonocular adverse event			
Investigator-defined hypertension			
Treatment-emergent hypertension — no. (%)	12 (8.4)	3 (2.2)	9 (6.4)
Mean change in blood pressure from baseline — mm Hg	0.1/0.3	-2/-2	-2/1
Key arterial nonfatal thromboembolic events — no. (%)			
Myocardial infarction	1 (0.7)	1 (0.7)	3 (2.1)
Stroke	1 (0.7)	0	1 (0.7)
Cerebral infarction	0	1 (0.7)	0
Death — no. (%)	2 (1.4)††	3 (2.2)	2 (1.4)
Vascular cause (APTC criteria)	1 (0.7)‡‡	1 (0.7)‡‡	2 (1.4)§§
Nonvascular cause	1 (0.7)¶¶	2 (1.5)	0
Nonocular hemorrhage — no. (%)			
Reported as a serious adverse event	0	2 (1.5)	3 (2.1)
Total serious or nonserious events***	3 (2.1)	7 (5.1)	9 (6.4)

* APTC denotes Antiplatelet Trialists' Collaboration.

† Events were categorized as presumed endophthalmitis in cases in which intravitreal or systemic antibiotics were administered.

‡ Vitreous culture was positive for *Staphylococcus epidermidis*.

§ One patient had two episodes of intraocular inflammation that were reported as uveitis, but one of the episodes was classified as presumed endophthalmitis because it was treated with systemic antibiotics. In neither of these two episodes was a vitreous culture obtained, and neither was treated with intravitreal antibiotics.

¶ One patient had two episodes of rhegmatogenous retinal detachment.

|| No serious or nonserious adverse events associated with retinal tears were reported.

** Ocular inflammation (regardless of the cause) was determined on the basis of slit-lamp examination. The grading system used to evaluate intraocular inflammation is outlined in Tables 2 and 3 of the Supplementary Appendix.

†† One patient died after withdrawing from the study because of an adverse event.

‡‡ One patient died from cardiac arrest.

§§ One patient died from cardiac failure, and one patient died from worsening of chronic heart failure.

¶¶ One patient died from chronic obstructive pulmonary disease.

||| One patient died from respiratory arrest and one from viral syndrome.

***All nonocular hemorrhagic adverse events are listed in Table 4 of the Supplementary Appendix.

the study and continued to receive ranibizumab had an intestinal perforation, a known risk associated with systemic bevacizumab therapy.¹⁹

We observed immunoreactivity to ranibizumab in a percentage of patients in all treatment groups (1.5% in the verteporfin group, 3.2% in the 0.3-mg group, and 0.8% in the 0.5-mg group) before any exposure to ranibizumab. Monitoring of immunoreactivity during the first treatment year revealed no increase from baseline in the number of patients testing positive in the verteporfin group or the 0.3-mg group (1.6% in each group at 12 months), whereas the 0.5-mg group showed an increase to 3.9% of patients at 12 months. Although the small number of patients with immunoreactivity precludes drawing definitive conclusions, proportionately more ranibizumab-treated patients who were immunoreactive at any point had adverse events associated with intraocular inflammation (3 of 6 in the 0.3-mg group and 3 of 5 in the 0.5-mg group, as compared with 0 of 3 in the verteporfin group) than did patients who were never immunoreactive (11 of 127 in the 0.3-mg group and 17 of 129 in the 0.5-mg group, as compared with 3 of 129 in the verteporfin group). The presence or absence of immunoreactivity appeared to be unrelated to end points associated with visual acuity or nonocular adverse events potentially related to immunoreactivity.

DISCUSSION

Our study demonstrated that ranibizumab prevents central vision loss and improves mean visual acuity at 1 year. In this study, monthly intravitreal injections of ranibizumab were superior in efficacy to verteporfin therapy. Although our study was not designed to evaluate the superiority of one ranibizumab dose over the other, efficacy results suggest a dose–response effect.

Intravitreal injections of ranibizumab were associated with a low rate of serious ocular adverse events, including such key events as presumed endophthalmitis, severe intraocular inflammation, and retinal detachment (each of which was reported in less than 1% of the pooled ranibizumab-treated patients and in less than 0.1% of ranibizumab injections). The ocular safety profiles for the three treatment groups revealed no overall imbalance in serious and nonserious adverse events, although there were trends toward increased rates of intraocular inflammation (gener-

ally mild), cataract (consistently mild or moderate), and nonocular hemorrhage with ranibizumab. The rates of intraocular inflammation and cataract in the ranibizumab groups were similar to those for ranibizumab-treated patients in the MARINA study.¹⁴ However, the rates of these events in the verteporfin group in our study were lower than the rates in the sham-injection group in the MARINA study.¹⁴

Regarding adverse events that potentially reflect systemic VEGF inhibition, no adverse events of proteinuria were reported and no imbalance in adverse events of hypertension or in blood-pressure measurements was noted in either our study or the MARINA study. In both studies, ranibizumab-treated patients had a higher percentage of nonocular hemorrhages than did patients who did not receive ranibizumab, and patients treated with a 0.5-mg dose had a higher rate of APTC-classified arterial thromboembolic events than did those who received a 0.3-mg dose or verteporfin therapy (Table 3). Since our study was not designed to distinguish small differences in rare adverse events among treatment groups, the clinical significance of these trends is unclear and requires further attention. In the MARINA study, with 2 years of study treatment, the rates of events classified as arterial thromboembolism according to APTC criteria were similar among the treatment groups.¹³ Follow-up is continuing through 2 years of treatment in our study to identify these events. The clinical significance of immunoreactivity to ranibizumab observed with the assay method used in our study and in the MARINA study is also not clear.

In summary, the ANCHOR study showed that ranibizumab administered monthly by intravitreal injection was superior in efficacy to photodynamic therapy with verteporfin in patients with subfoveal, predominantly classic choroidal neovascularization associated with age-related macular degeneration. The first-year results of our study and the 2-year results of the MARINA study, considered together, demonstrate that ranibizumab was effective with an acceptable adverse-event profile in the treatment of all angiographic subtypes of choroidal neovascularization associated with age-related macular degeneration.

Supported by Genentech and Novartis Pharma.

Dr. Brown reports having received consulting fees from Genentech, Alcon, Eyetechnology, Novartis, and Allergan; lecture fees from Genentech and Eyetechnology; and grant support from Alcon, Acuity Pharmaceuticals, Allergan, Alimera, Eyetechnology, Pfizer,

Novartis, Genentech, Eli Lilly, Oxigene, and the Diabetic Retinopathy Clinical Research network; and having an equity interest in Pfizer. Dr. Kaiser reports having received consulting fees from Genentech, Alcon, Allergan, and Novartis and having received lecture fees from Novartis and Genentech. Dr. Michels reports having received consulting fees from Genentech and Pfizer–(OSI) Eyeteck and lecture fees from Pfizer–(OSI) Eyeteck, Novartis, and Genentech. Dr. Soubrane reports having received consulting fees from Alcon, Allergan, Thea, Alimera, Pfizer–(OSI) Eyeteck, and Novartis and lecture fees from Pfizer, Alcon, Thea, and Novartis. Dr. Heier reports having received consulting fees from Genentech, Eyeteck, Oxigene, Novartis, Allergan, Genzyme, iScience, ISTA, Pfizer, Regeneron, Theragenics, VisionCare, and Jerini; lecture fees from Genentech, Eyeteck, Jerini, and Allergan; and grant support from Genentech, Eyeteck, Pfizer, and Eli Lilly Theragenics. Dr. Kim reports being a full-time employee of Genentech and having received stock options. Dr. Sy and Dr. Schneider report being full-time employees of Genentech, hold-

ing an equity interest in the company, and having received stock options. No other potential conflict of interest relevant to this article was reported.

We are indebted to the patients who participated in this study, their families, and the research teams at each site; to the members of the data and safety monitoring committee: Frederick L. Ferris III, M.D. (chair), Susan B. Bressler, M.D., Stuart L. Fine, M.D., and Marian Fisher, Ph.D.; to the members of the University of Wisconsin Fundus Photograph Reading Center; to the members of the data-coordinating center (Statistics Collaborative); to members of the Genentech Clinical Operations organization for their invaluable assistance in the conduct of this study; to Charles Semba, M.D., Naveed Shams, M.D., Ph.D., James F. Ward, Ph.D., Lisa Damico, Ph.D., and Steven Butler, Ph.D., of Genentech for their critical comments and review throughout the design, conduct, and analysis of the study; and to staff members at Genentech for their assistance in the preparation of the manuscript.

APPENDIX

The following principal investigators were members of the ANCHOR Study Group: T. Aaberg, Associated Retinal Consultants, Grand Rapids, MI; P. Abraham, Black Hills Regional Eye Institute, Rapid City, SD; L. Akduman, Saint Louis University Eye Institute, St. Louis; D. Alfaro III, Retina Consultants of Charleston, Charleston, SC; A. Antoszyk, Southeast Clinical Research Associates, Charlotte, NC; J. Arnold, Marsden Eye Research, Parramatta, Australia; C. Awl, Retina Vitreous Associates, Nashville; P. Beer, New Lions Eye Institute, Slingerlands, NY; J. Belmont, Retina Diagnostic and Treatment, Philadelphia; B. Berger, Retina Research Center, Austin, TX; D. Berinstein, Retina Group of Washington, Fairfax, VA; R. Bhisitkul, University of California at San Francisco School of Medicine, San Francisco; D. Boyer, Retina–Vitreous Associates, Beverly Hills, CA; W. Bridges, Western Carolina Retinal Associates, Asheville, NC; H. Brooks, Jr., Southern Vitreoretinal Associates, Tallahassee, FL; D. Brown, Vitreoretinal Consultants, Houston; T. Ciulla, Midwest Eye Institute, Indianapolis; W. Clark, Palmetto Retina Center, Columbia, SC; T. Connor, Medical College of Wisconsin, Milwaukee; S. Cousins, Bascom Palmer Eye Institute, Palm Beach Gardens, FL; F. Devin, Clinique Monticelli, Marseilles, France; W. Dunn, Florida Retina Institute, Daytona Beach; A. Eaton, Retina Health Center, Fort Myers, FL; S. Fekrat, Duke University Eye Center, Durham, NC; C. Foja, Universitätsklinikum Leipzig, Leipzig, Germany; B. Foster, New England Retina Consultants, West Springfield, MA; A. Gaudric, Hôpital Lariboisière, Paris; M. Gilles, Save Sight Institute, Sydney; D. Glaser, Retina Associates of St. Louis, Florissant, MO; B. Godley, Retina Specialists, Desoto, TX; V. Gonzalez, Valley Retina Institute, McAllen, TX; R. Goodart, Rocky Mountain Retina Consultants, Salt Lake City; R. Guymer, University of Melbourne, Centre for Eye Research Australia, East Melbourne, Australia; L. Halperin, Retina Vitreous Consultants, Fort Lauderdale, FL; J. Heier, Ophthalmic Consultants of Boston, Boston; F. Holz, Universitätsklinikum Bonn, Bonn, Germany; B. Hubbard, Emory University, Atlanta; H. Hudson, Retina Centers, Tucson, AZ; D. Ie, Delaware Valley Retina Associates, Lawrenceville, NJ; M. Johnson, University of Michigan, Ann Arbor; A. Jousseaume, Universitätsklinikum Köln, Cologne, Germany; P. Kaiser, Cleveland Clinic Foundation, Cole Eye Institute, Cleveland; B. Kuppermann, University of California at Irvine, Irvine; M. Lomeo, Midwest Retina, Columbus, OH; C. MacDonald, University of Texas Health Science Center, San Antonio; D. Marcus, Southeast Retina Center, Augusta, GA; A. Martidis, Retina Diagnostic and Treatment, Philadelphia; J. Martinez, Austin Retina Associates, Austin, TX; D. Maxwell, Jr., Retinal Associates of Oklahoma, Oklahoma City; T. McMillan, Southeastern Retina Associates, Knoxville, TN; M. Michels, Palm Beach Gardens, FL; D. Miller, Retina Associates of Cleveland, Beachwood, OH; P. Michell, Westmead Hospital, Westmead, Australia; I. Orgel, Retina Vitreous Associates, Toledo, OH; R. Park, University of Arizona, Tucson; M. Paul, Danbury Eye Physicians and Surgeons, Danbury, CT; P. Pavan, University of South Florida, Tampa; M. Petersen, Cincinnati Eye Institute, Cincinnati; J. Prentsky, Pennsylvania Retina Specialists, Camp Hill, PA; P. Raskauskas, Retina Consultants of Southwest Florida, Fort Myers; E. Reichel, New England Eye Center, Boston; D. Reid, Retina Associates, Annapolis, MD; P. Richmond, Central Florida Retina, Orlando; W. Rodden, Retina and Vitreous Center of Southern Oregon, Ashland, OR; P. Rosenfeld, Bascom Palmer Eye Institute, Miami; P. Runge, Ophthalmic Consultants, Sarasota, FL; S. Sadda, Doheny Eye Institute, Los Angeles; S. Sanislo, California Vitreoretinal Research Center, Menlo Park; S. Schwartz, Bascom Palmer Eye Institute, Palm Beach Gardens, FL; A. Seres, Semmelweis University, Budapest, Hungary; M. Singer, Medical Center Ophthalmology Associates, San Antonio, TX; G. Soubrane, Clinique d’Ophtalmologie, University of Paris XII, Créteil, France; P. Soucek, University Hospital Vinohrady, Prague, Czech Republic; W. Stern, Northern California Retina–Vitreous Associates, Mountain View; G. Stoller, Ophthalmic Consultants of Long Island, Rockville Centre, NY; J. Thompson, Retina Specialists, Towson, MD; D. Tom, New England Retina Associates, Hamden, CT; R. Torti, Retina Specialists, Desoto, TX; M. Trese, Associated Retinal Consultants, Royal Oak, MI; E. van Kuijk, University of Texas Medical Branch, Galveston; T. Verstaeten, Allegheny General Hospital, Pittsburgh; K. Warren, University of Kansas Medical Center, Kansas City; H. Weiss, Retina Consultants of Michigan, Southfield; J. Weiss, Retina Associates of South Florida, Margate, FL; C. Wells, Vitreoretinal Associates, Seattle; S. Wolf, Universitätsklinikum Leipzig, Leipzig, Germany; and K. Zhang, John Moran Eye Center, University of Utah, Salt Lake City.

REFERENCES

1. Bressler NM. Age-related macular degeneration is the leading cause of blindness. *JAMA* 2004;291:1900-1.
2. Friedman DS, O’Colmain BJ, Munoz B, et al. Prevalence of age-related macular degeneration in the United States. *Arch Ophthalmol* 2004;122:564-72.
3. Resnikoff S, Pascolini D, Etya’ale D, et al. Global data on visual impairment in the year 2002. *Bull World Health Organ* 2004;82:844-51.
4. Augood C, Fletcher A, Bentham G, et al. Methods for a population-based study of the prevalence of and risk factors for age-related maculopathy and macular degeneration in elderly European populations: the EUREYE study. *Ophthalmic Epidemiol* 2004;11:117-29.
5. Ferris FL III, Fine SL, Hyman L. Age-related macular degeneration and blindness due to neovascular maculopathy. *Arch Ophthalmol* 1984;102:1640-2.
6. Macular Photocoagulation Study Group. Subfoveal neovascular lesions in age-related macular degeneration. *Arch Ophthalmol* 1984;102:1640-2.

- ed macular degeneration: guidelines for evaluation and treatment in the Macular Photocoagulation Study. *Arch Ophthalmol* 1991;109:1242-57.
7. Ali F, Chan WC, Stevenson MR, Muldrew KA, Chakravarthy U. Morphometric analysis of angiograms of exudative lesions in age-related macular degeneration. *Arch Ophthalmol* 2004;122:710-5.
 8. Pauleikhoff D. Neovascular age-related macular degeneration: natural history and treatment outcomes. *Retina* 2005;25:1065-84.
 9. Photodynamic therapy of subfoveal choroidal neovascularization in age-related macular degeneration with verteporfin: one-year results of 2 randomized clinical trials — TAP report. *Arch Ophthalmol* 1999;117:1329-45. [Erratum, *Arch Ophthalmol* 2000;118:488.]
 10. Verteporfin in Photodynamic Therapy Study Group. Verteporfin therapy of subfoveal choroidal neovascularization in age-related macular degeneration: two-year results of a randomized clinical trial including lesions with occult with no classic choroidal neovascularization — Verteporfin In Photodynamic Therapy (VIP) report 2. *Am J Ophthalmol* 2001;131:541-60.
 11. Bressler NM. Photodynamic therapy of subfoveal choroidal neovascularization in age-related macular degeneration with verteporfin: two-year results of 2 randomized clinical trials — TAP report 2. *Arch Ophthalmol* 2001;119:198-207.
 12. Guidelines for using verteporfin (Visudyne) in photodynamic therapy for choroidal neovascularization due to age-related macular degeneration and other causes: update. *Retina* 2005;25:119-34.
 13. Gragoudas ES, Adamis AP, Cunningham ET Jr, Feinsod M, Guyer DR. Pegaptanib for neovascular age-related macular degeneration. *N Engl J Med* 2004;351:2805-16.
 14. Rosenfeld PJ, Brown DM, Heier JS, et al. Ranibizumab for neovascular age-related macular degeneration. *N Engl J Med* 2006;355:1419-31.
 15. Heier JS, Boyer DS, Ciulla TA, et al. Ranibizumab in combination with verteporfin photodynamic therapy in neovascular age-related macular degeneration (FOCUS): year 1 results. *Arch Ophthalmol* (in press).
 16. Cochran WG. Some methods for strengthening the common chi-square tests. *Biometrics* 1954;10:417-51.
 17. Hochberg Y. A sharper Bonferroni procedure for multiple tests of significance. *Biometrika* 1988;75:800-2.
 18. Visudyne. East Hanover, NJ: Novartis Pharmaceuticals, 2005 (package insert).
 19. Avastin. South San Francisco, CA: Genentech, 2004 (package insert).
 20. Antiplatelet Trialists' Collaboration. Collaborative overview of randomised trials of antiplatelet therapy. I. Prevention of death, myocardial infarction, and stroke by prolonged antiplatelet therapy in various categories of patients. *BMJ* 1994;308:81-106. [Erratum, *BMJ* 1994;308:1540.]

Copyright © 2006 Massachusetts Medical Society.